

A Cadaveric Study of Sciatic Nerve and It's Level of Bifurcation

MUTHU KUMAR T., SRIMATHI, ANANDA RANI, SUMATHI LATHA

ABSTRACT

Sciatic nerve, the thickest nerve in the body, formed in the pelvis, emerges through greater sciatic foramen to enter the gluteal region, then the nerve passes on the back of thigh to reach the superior angle of popliteal fossa and bifurcates into tibial and common peroneal nerves. But the level of bifurcation

varies. The assessment of level of bifurcation of sciatic nerve were available minimal in the Indian literature. So this study was taken and it focus on the frequency of the level of bifurcation of sciatic nerve. For this 50 free lower limbs were dissected. The results were compared with previous reports.

Key Words: Sciatic nerve, Tibial nerve, Common peroneal nerve

INTRODUCTION

Sciatic nerve is the thickest nerve in the body. It is regarded as the continuation of upper band of sacral plexus [1]. It has a root value of L4S1-2. It is formed in the pelvis, leaves the pelvis through greater sciatic foramen usually below the level of piriformis and enters the gluteal region, passing behind the hip joint and enters the back of the thigh upto the superior angle of popliteal fossa, where it terminates into tibial nerve and common peroneal nerve. Sciatic nerve and through it's branches supplies the entire lower limb except the front of thigh and the medial compartment of thigh which are supplied by femoral nerve and obturator nerve respectively.

The sciatic nerve is the most frequently injured lower extremity nerve [2]. It is commonly injured in posterior dislocation of hip [3] and in fracture of hip joint [4]. It is also injured during total hip replacement surgery and in hemiarthroplasty of hip [5]. It is one of the nerve commonly injured due to intramuscular injections [6]. Positioning of individuals during gynaecological surgeries like hysterectomy and dilatation and curettage can affect sciatic nerve [7]. Sciatic nerve is also affected in the entrapment neuropathy called Piriformis syndrome [8]. Peroneal division is more prone to injury from injections and hip fracture as it lies more posteriorly. Patient will present with foot drop secondary to loss of dorsiflexion and eversion of foot as well as inability to extend the foot. Injury to tibial division of sciatic nerve produces loss of plantar flexion and inversion of the foot as well as loss of flexion of ankle [9]. Patients will present with burning and hyperesthetic sole of foot. In Popliteal nerve block for the surgery of foot and ankle, sciatic nerve is approached 5cm or 7cm above the transverse popliteal crease [10, 11]. This study makes an attempt to locate the level of bifurcation of sciatic nerve.

MATERIALS AND METHODS

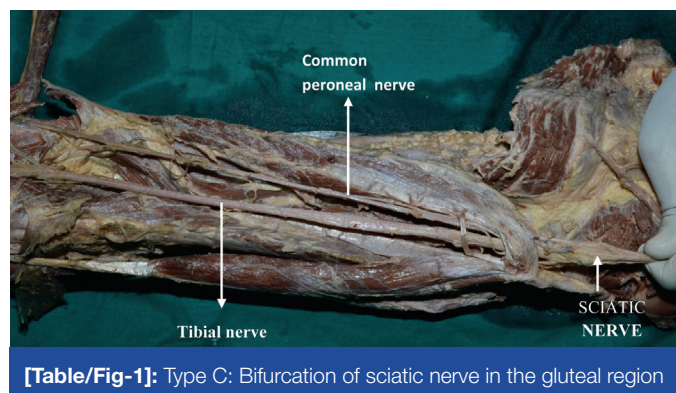
About fifty free lower limbs available in the department of anatomy, Sri Ramachandra Medical College, Sri Ramachandra University were utilized for the study. Sciatic nerve is dissected and the level of bifurcation is recorded. It's interpreted with previous studies.

RESULTS

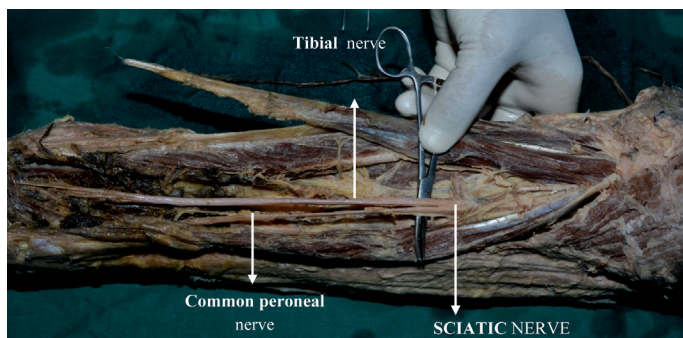
The results are grouped into various categories:

- Type A₁: Undivided nerve emerges above the piriformis
- Type A₂: Undivided nerve emerges through the piriformis.
- Type A₃: Undivided nerve emerges below the piriformis.
- Type B₁: Divided nerve emerges above the piriformis.
- Type B₂: Divided nerve emerges through the piriformis.
- Type B₃: Divided nerve emerges below the piriformis.
- Type C: Division of sciatic nerve in the gluteal region [Table/Fig-1].
- Type D: Division of sciatic nerve in the upper thigh [Table/Fig-2].
- Type E: Division of sciatic nerve in the middle thigh [Table/Fig-3].
- Type F: Division of sciatic nerve in the lower thigh [Table/Fig-4].
- Type G: Division of sciatic nerve in the popliteal fossa [Table/Fig-5].

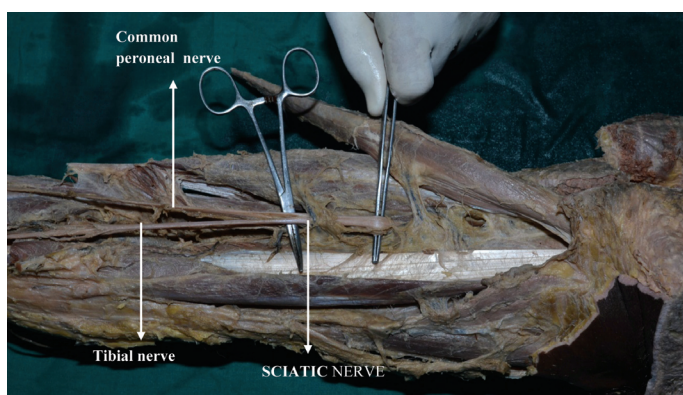
- In all the fifty specimens dissected, sciatic nerve emerges undivided below the piriformis (Type A₃ 100%).
- Division of sciatic nerve, in the gluteal region, type C, is seen in 4 limbs (8%)
- Division of sciatic nerve in the upper thigh, type D, is observed in 7 limbs (14%)
- Division of sciatic nerve in the middle thigh, type E, is present in 19 limbs (38%)
- Division of sciatic nerve in the lower thigh, type F, is seen in 4 limbs (8%)
- Division sciatic nerve in the popliteal fossa, type G is present in 16 limbs (32%) [Table/Fig-6].



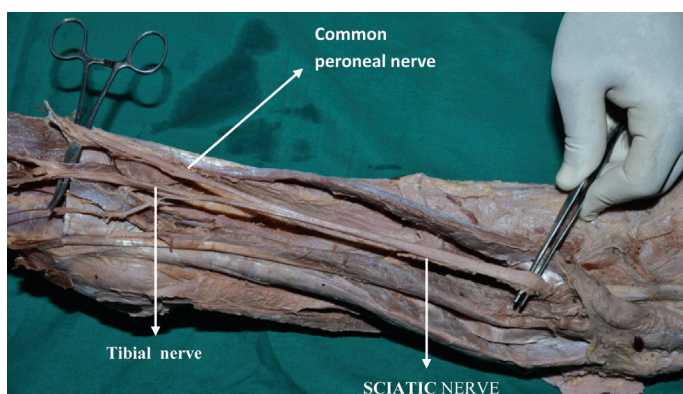
[Table/Fig-1]: Type C: Bifurcation of sciatic nerve in the gluteal region



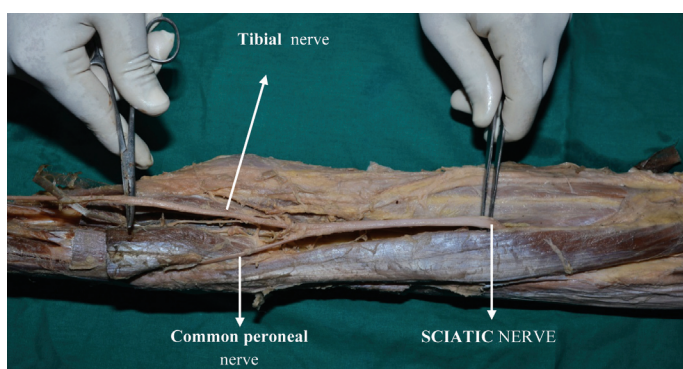
[Table/Fig-2]: Type D: Sciatic nerve bifurcation in the upper thigh



[Table/Fig-3]: Type E: Bifurcation of sciatic nerve in the middle thigh



[Table/Fig-4]: Type F: Sciatic nerve bifurcation in the lower thigh



[Table/Fig-5]: Type G: Sciatic nerve bifurcation in the popliteal fossa

DISCUSSION

In the present study all the 50 specimens presents with emergence of undivided sciatic nerve below the piriformis. However Guvencer et al., observed undivided sciatic nerve below the piriformis in 52%. Beaton et al., reported in 90%, Ewa okraszewska observed in 81%, Ugrenovic observed in 96%, Kukiriza observed in 77.5%, Prakash et al., observed in 83.7%, Pokorny et al. observed in 79%.

Type*	No. of limbs†	%‡
A ₃	50	100
C	4	8
D	7	14
E	19	38
F	4	8
G	16	32

[Table/Fig-6]: Level of bifurcation of sciatic nerve and it's frequency.

* Level of sciatic nerve bifurcation; †Number of limbs; ‡Percentage

In the present study type C variety, the bifurcation of sciatic nerve in the gluteal region observed in 8% and Prakash et al., observed in 2.3%.

Bifurcation of sciatic nerve in the upper thigh, type D variety, observed in 14% in the present study, where as Prakash et al., observed in 3.5%.

Middle thigh sciatic nerve bifurcation, type E variety observed in 38% in the present study, and Prakash et al., observed in 2.3% .

Lower thigh sciatic nerve bifurcation, type F observed in 8% in the present study and Prakash et al., observed in 40.7%. Ugrenovic observed the division of sciatic nerve in the gluteal region and thigh together in 27.5%, and Ewa observed the same in 19%.

Division of sciatic nerve in the popliteal fossa is observed in 32% in the present study, Ugrenovic reported in 72.5%, Ewa observed in 62% and Prakash reported in 35%. The level of bifurcation of sciatic nerve when compared with other studies is tabulated below [Table/Fig-7].

Author	Undivided nerve from the pelvis	Division the gluteal region	Division in the thigh	Division in the popliteal fossa
Beaton (12)	90%			
Guvencer (13)	52%			
Pokorny (14)	79%			
Ugrenovic (15)	96%	27.5%		72.5%
Ewa Okraszewska (16)	81%	19%		62%
Kukiriza (17)	77.5%			
Prakash(18)	83%	2.3%	46.5%	35%
Present study	100%	8%	60%	32%

[Table/Fig-7]: Level of bifurcation of sciatic nerve as compared with other studies.

In the present study the division of sciatic nerve is observed maximum in the middle of the thigh at 38% and in the popliteal fossa in 32%

REFERENCES

- [1] Peter L Williams, Mark S Dyson, *Gray's Anatomy*. 36 th edition. ELBS and Churchill Livingstone , in neurology, p. 1145.
- [2] George T Tindall, Paul R Cooper. *The practice of neurosurgery*, 1 edition. Williams and Wilkins. vol. 3.
- [3] Robert F Hillyard, Jolene Fox, RN. Sciatic nerve injuries associated with traumatic posterior hip dislocation. *American Journal of Emergency Medicine*. 2003 November;21(7):545-48.
- [4] Paul R Fassler, Marc F Swiontkowski, Anthony W Kilroy, Milton L. Routf, Jr, Nashville, et al. Injury of the Sciatic Nerve Associated with Acetabular Fracture .*The Journal of Bone and joint Surgery*, 1993 Aug. 75-A: 8, 1157.
- [5] Pandian JD, Bose S, Daniel V, Singh Y, Abraham AP. Nerve injuries following intramuscular injections: a clinical and neuro-physiological

- study from Northwest India. *J Peripher Nerv Syst.* 2006 Jun;11(2): 165-71.
- [6] Batres F, Barclay DL. Sciatic nerve injury during gynecologic procedures using the lithotomy position. *Obstet Gynecol.* 1983 Sep; 62(3 Suppl):92s-94s.
- [7] Daniel H Kim, Judith A Murovic, Robert Tiel, David G Kline. Management and outcomes in 353 surgically treated sciatic nerve lesions. *J Neurosurg* 2004;101:8-17.
- [8] David G. Kline, Daniel Kim, Rajiv Midha, Carter Harsh, Robert Tiel. Management and results of sciatic nerve injuries: a 24-year Experience. *J Neurosurg* 1998;89:13-23.
- [9] Timir Banerjee, Colin D Hall. Sciatic entrapment neuropathy Case report. *Neurosurg.* 1976 August ;45:216-17.
- [10] Duane K Rorie, David E Byer, David O Nelson, Rungson Sittipong, Kenneth A Johnson. Assessment of Block of the Sciatic Nerve in the Popliteal Fossa. *Anesth Analg* 1980 May; 59:371-376
- [11] Jerry D Vloka, Admir Hadžić, Ernest April, Daniel M. Thys The Division of the Sciatic Nerve in the Popliteal Fossa: Anatomical Implications for Popliteal Nerve Blockade. *Anesth Analg* 2001 January; 92:215-17.
- [12] Lindsay E Beaton, and Barry J Anson. Chicago, Illinois The Sciatic Nerve And The Piriformis Muscle: Their Interrelation A Possible Cause of Coccygodynia. *The Journal of Bone and joint Surgery.* 1938 July(20);3: 686.
- [13] Güvençer M, İyem C, Akyer P, Tetik S, Naderi S. Variations in the high division of the sciatic nerve and relationship between the sciatic nerve and the piriformis. *Turk Neurosurg.* 2009 Apr; 19(2):139-44.
- [14] Ugrenovic S, Jovanovic I, Krstic V, Stojanovic V, Vasovic L, Antic S, et al. The level of the sciatic nerve division and its relations to the piriform muscle. *Vojnosanit Pregl* 2005 Jan; 62(1):45-9.
- [15] Ewa Okraszewska, Łukasz Migdalski, Kazimierz S. Jedrzejewski, Wojciech Bolanowski. Sciatic nerve variations in some studies on the Polish population and its statistical significance. *Folia Morphol* Vol. 61, No. 4, pp. 277-82.
- [16] J Kukiriza, H Kiryowa, J Turyabahika, J Ochieng CBR Ibingira. East and Levels of Bifurcation of the Sciatic Nerve among Ugandans at School of Biomedical. *Central African Journal of Surgery.* July/August 2010;2(15):69.
- [17] Prakash, Bhardwaj AK, Devi MN, Sridevi NS, Rao PK, Singh G. Sciatic nerve division: a cadaver study in the Indian population and review of the literature. *Singapore Med J* 2010; 51(9): 721.
- [18] Pokorny D, David Jahoda, David Veigl. Topographic variations of the relationship of the sciatic nerve and the piriformis muscle and its relevance to palsy after total hip arthroplasty. *Surgical and radiological anatomy* 2006;28:88-91.

AUTHOR(S):

1. Dr. Muthu Kumar T.
2. Dr. Srimathi
3. Dr. Ananda Rani
4. Dr. Sumathi Latha

PARTICULARS OF CONTRIBUTORS

1. MD, Associate professor, Department of Anatomy Sri Ramachandra Medical College and Research Institute, Porur, Chennai - 116.
2. MD, Associate professor Department of Anatomy Sri Ramachandra Medical College and Research Institute, Porur, Chennai - 116.
3. MS, Associate professor Department of Anatomy Sri Ramachandra Medical College and Research Institute, Porur, Chennai - 116.
4. MS, Associate professor Department of Anatomy Sri Ramachandra Medical College and Research Institute, Porur, Chennai - 116.

PLACE OF STUDY:

Sri Ramachandra Medical College and Research Institute, Porur, Chennai.

NAME, ADDRESS, TELEPHONE, E-MAIL ID OF THE CORRESPONDING AUTHOR:

Dr. Muthu Kumar T.
Associate Professor, Department of Anatomy,
Sri Ramachandra Medical College and Research Institute,
Porur, Chennai. Tamilnadu, India.
Phone: 9840467452
E mail: godmuthulakshmi74@yahoo.co.in.

DECLARATION ON COMPETING INTERESTS:

No competing Interests.

Date of Submission: **Oct 28, 2011**

Date of peer review: **Nov 21, 2011**

Date of acceptance: **Dec 10, 2011**

Date of Publishing: **Dec 25, 2011**